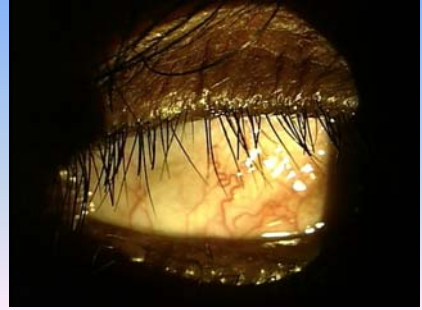
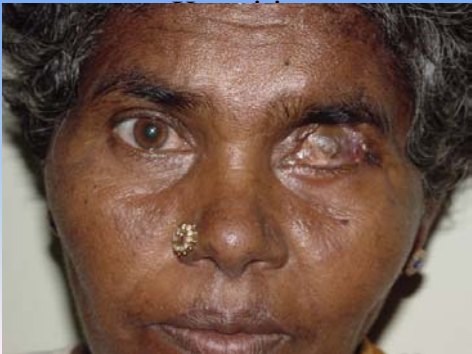


THE EYE IN MDT
1983 – 2004
Muthiah Arokia Rajan
Sacred Heart Leprosy Centre
Kumbakonam
Tamil Nadu
India

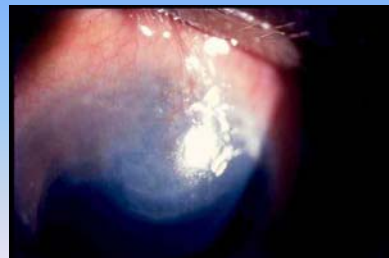Lagophthalmos Conjunctival
exposure more



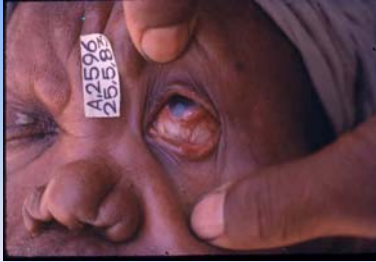Left Lag with Total exposure



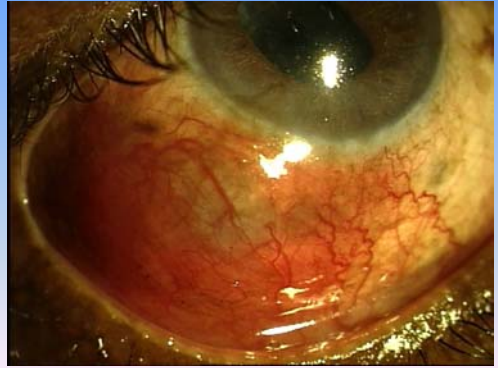
SPK with Corneal Blood vessels



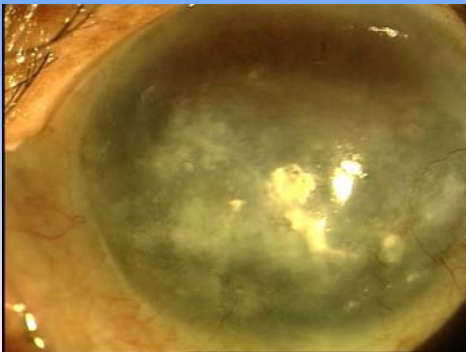
Episcleral Nodule



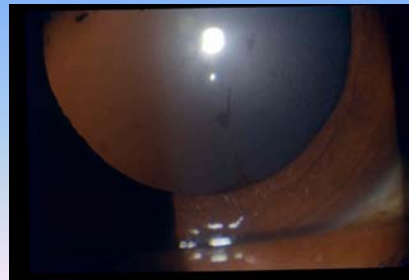
Episcleritis



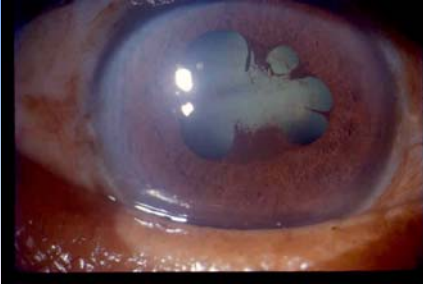
Interstitial Keratitis with new vessels



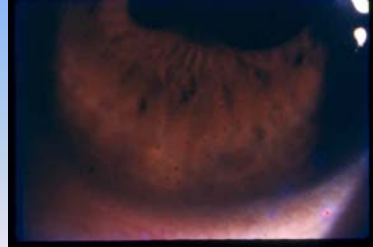
Iris tags on lens capsule



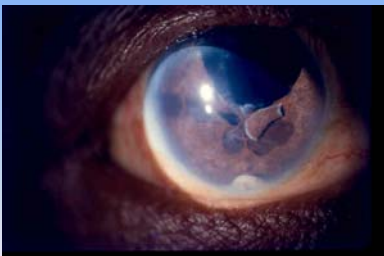
Iritis with extensive P S



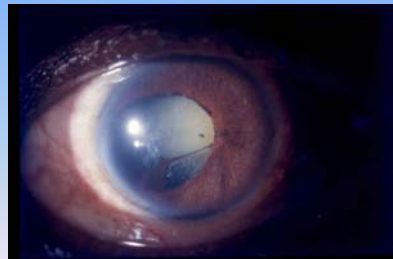
Keratic Precipitates



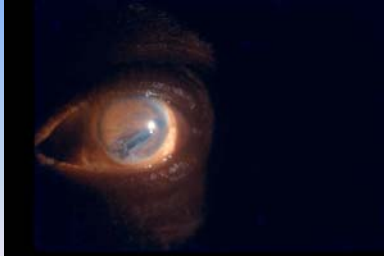Apakia with C I



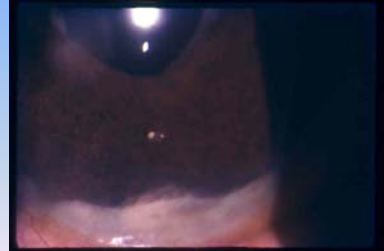
Severe Iris atrophy



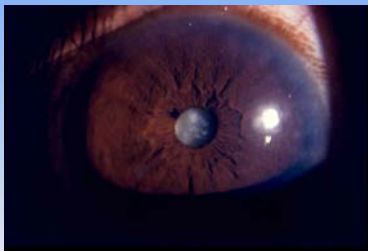Up drawn with Iris hole



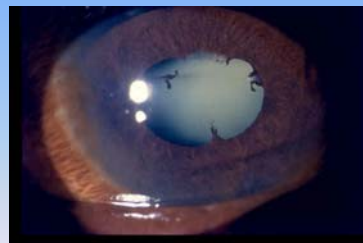Iris Pearls



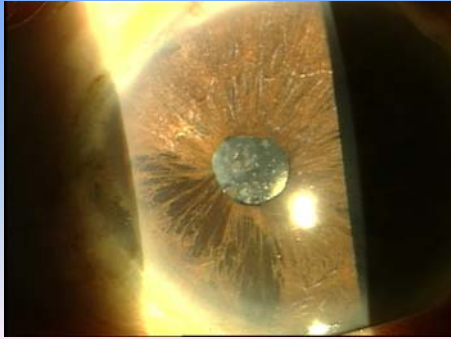
Iris pearls with complicated cataract



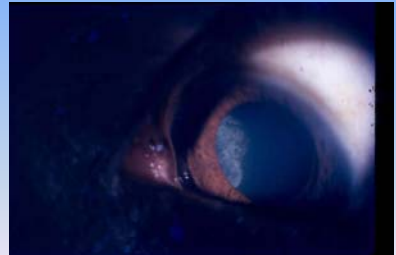Complicated cataract with extensive P S



Severe Iris with dense pupillary exudate



Complicated Steroid cataract



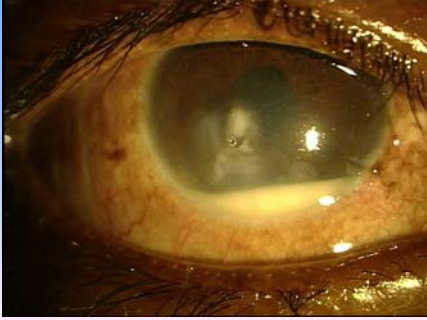
Complicated Steroid cataract



Corneal Ulcer



Corneal Ulcer with Hypobion



Intra Ocular lens implant in L L

