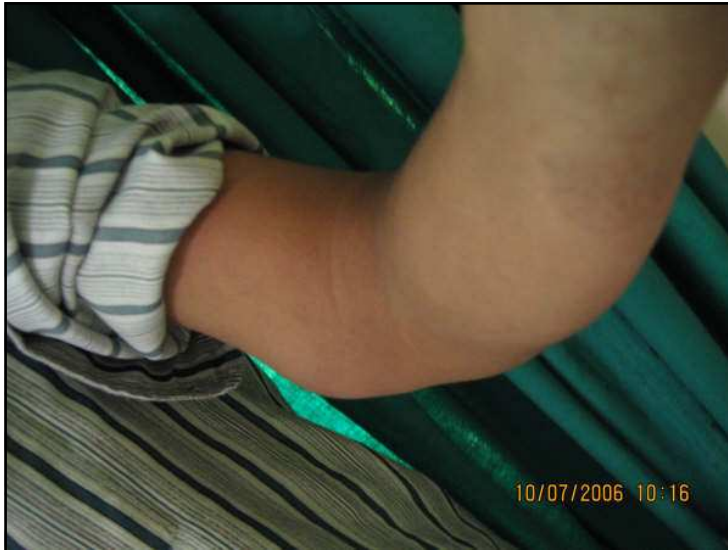



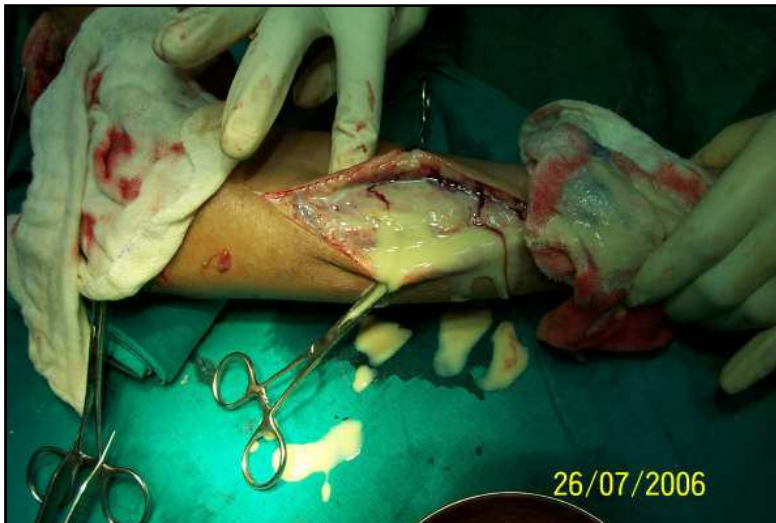Management
of ulnar nerve
abscess
Salafia A.

Abscess in the ulnar nerve. 19 years old boy leprosy patient. Large abscess a few days before surgery.

Credit for this slide:
Salafia A.

Leprosy Mailing List
August 31st, 2008

1



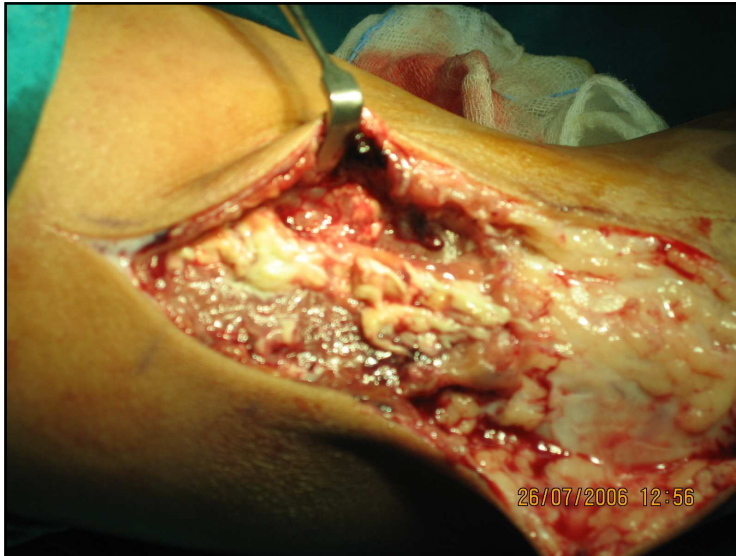
Management
of ulnar nerve
abscess
Salafia A.

Abscess in the ulnar nerve. 19 years old boy leprosy patient. Large quantity of pus (sterile) which had to be removed; pus does not disappear by itself.

Credit for this slide:
Salafia A.

Leprosy Mailing List
August 31st, 2008

2



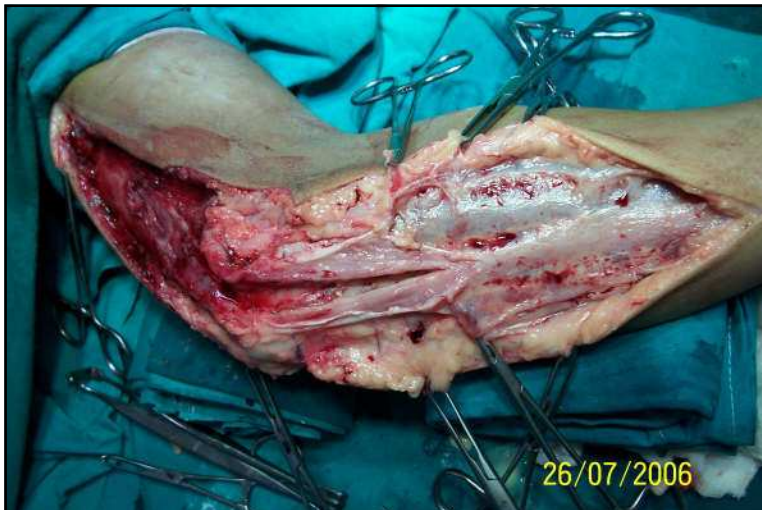
Management of ulnar nerve abscess
Salafia A.

The extend of the nerve damage can be appreciated by this slide.

Credit for this slide:
Salafia A.

Leprosy Mailing List
August 31st, 2008

3



Management of ulnar nerve abscess
Salafia A.

Abscess in the ulnar nerve. 19 years old boy leprosy patient. After an extensive, but necessary, dissection, very little if left of the ulnar nerve.

Credit for this slide:
Salafia A.

Leprosy Mailing List
August 31st, 2008

4

Management of nerve abscess (median n.)
Salafia A.

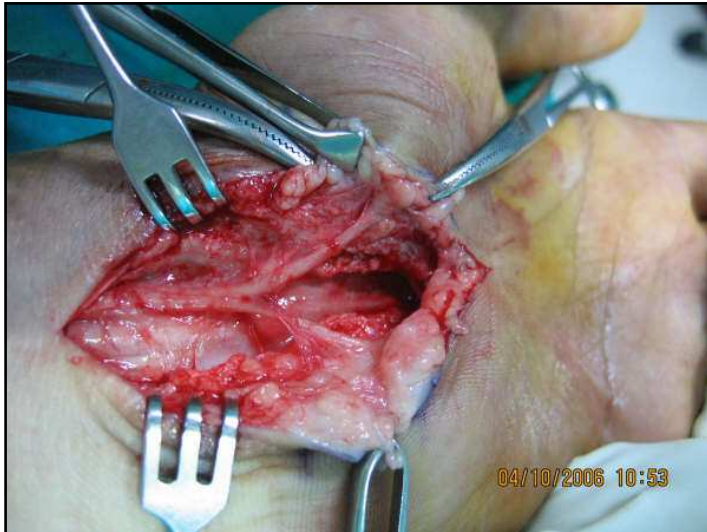
Abscess in the left median nerve. 19 years old boy leprosy patient. On the left: incision is extended and a new abscess (right) is found under the muscle.

Credit for this slide: Salafia A. Leprosy Mailing List August 31st, 2008 5

Management of nerve abscess (median n.)
Salafia A.

Abscess in the left median nerve. 19 years old boy leprosy patient. Incision extended in order to reach all the necrotic material.

Credit for this slide: Salafia A. Leprosy Mailing List August 31st, 2008 6



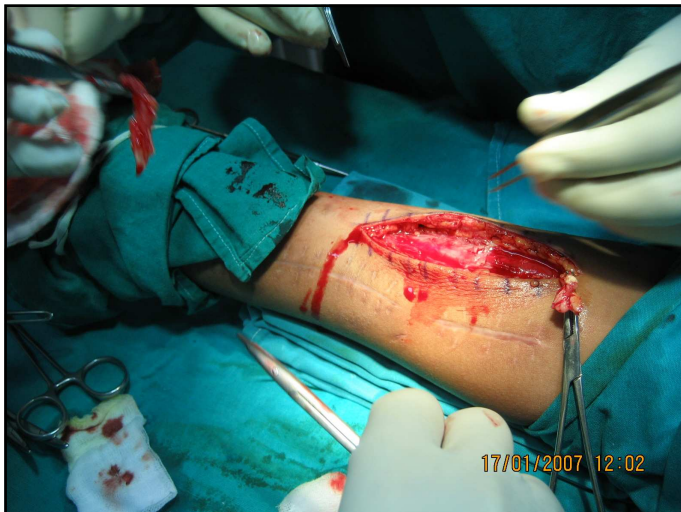Management of
nerve abscess
(median n.)
Salafia A.

Abscess in the left median nerve. 19 years old boy leprosy patient. We do not cut the carpal tunnel, we excise few mms. of the tunnel – in all cases - so as to prevent it from re-uniting.

Credit for this slide:
Salafia A.

Leprosy Mailing List
August 31st, 2008

7



Management of
nerve abscess
Salafia A

Abscess of the medial cutaneous of the forearm. Please note the scar along the lateral cutaneous of the forearm.

Credit for this slide:
Salafia A.

Leprosy Mailing List
August 31st, 2008

8

Management of
nerve abscess
Salafia A

- On the left: abscess in a branch of medial cutaneous of the forearm, close to the ulnar nerve.
- On the right: abscess on the lateral cutaneous of the forearm.

Credit for this slide:
Salafia A.

Leprosy Mailing List
August 31st, 2008

9

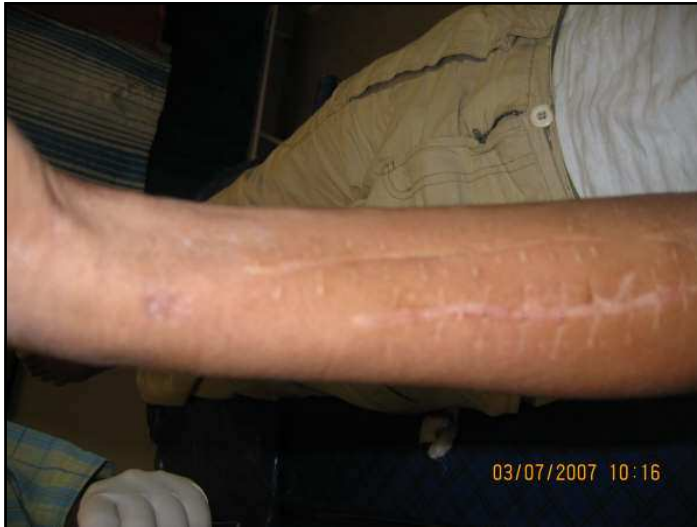Management
of nerve
abscess
Salafia A.

One abscess extending from the arm to the forearm.

Credit for this slide:
Salafia A.

Leprosy Mailing List
August 31st, 2008

10



Management
of nerve
abscess
Salafia A.

Scars. 19 years old boy leprosy patient. These scars are evidence of the many abscesses we had to excise.

Credit for this slide:
Salafia A.

Leprosy Mailing List
August 31st, 2008

11