

Diagnosis of leprosy

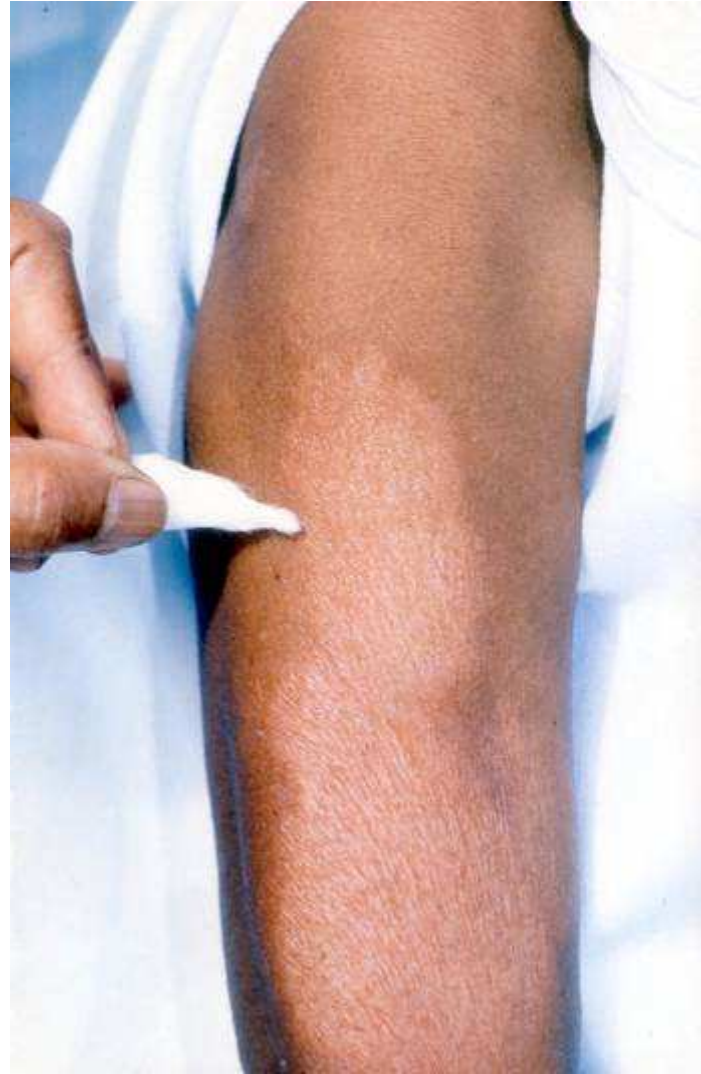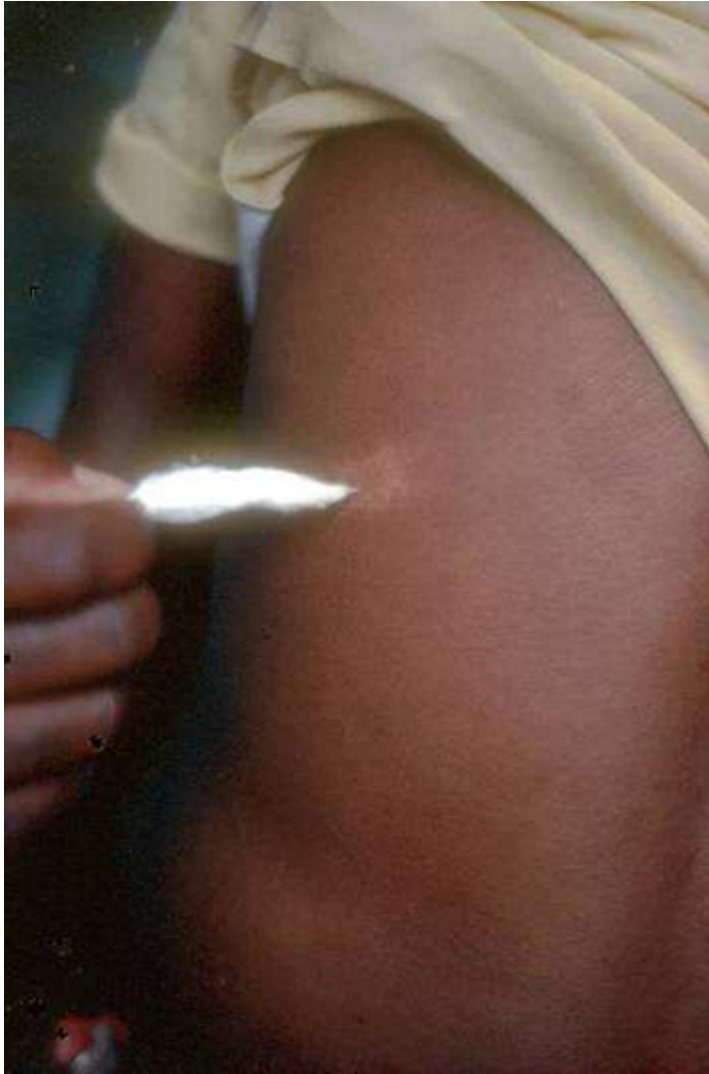The 1st cardinal sign of leprosy

**Salvatore Noto, Pieter A M Schreuder
Leprosy mailing list, May 2010**

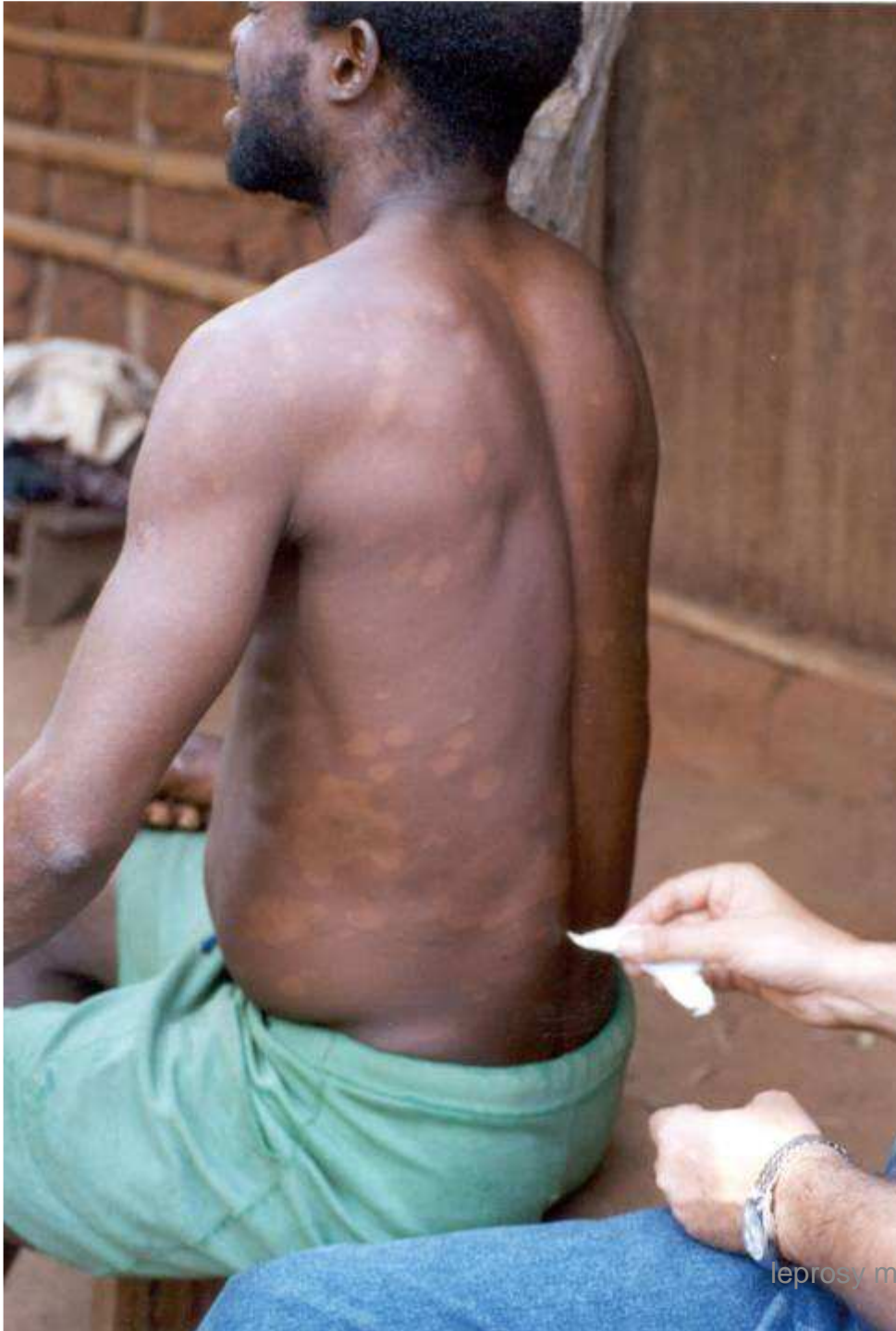The 1st cardinal sign of leprosy

“Skin patch with loss of sensation”

Testing for loss of sensation



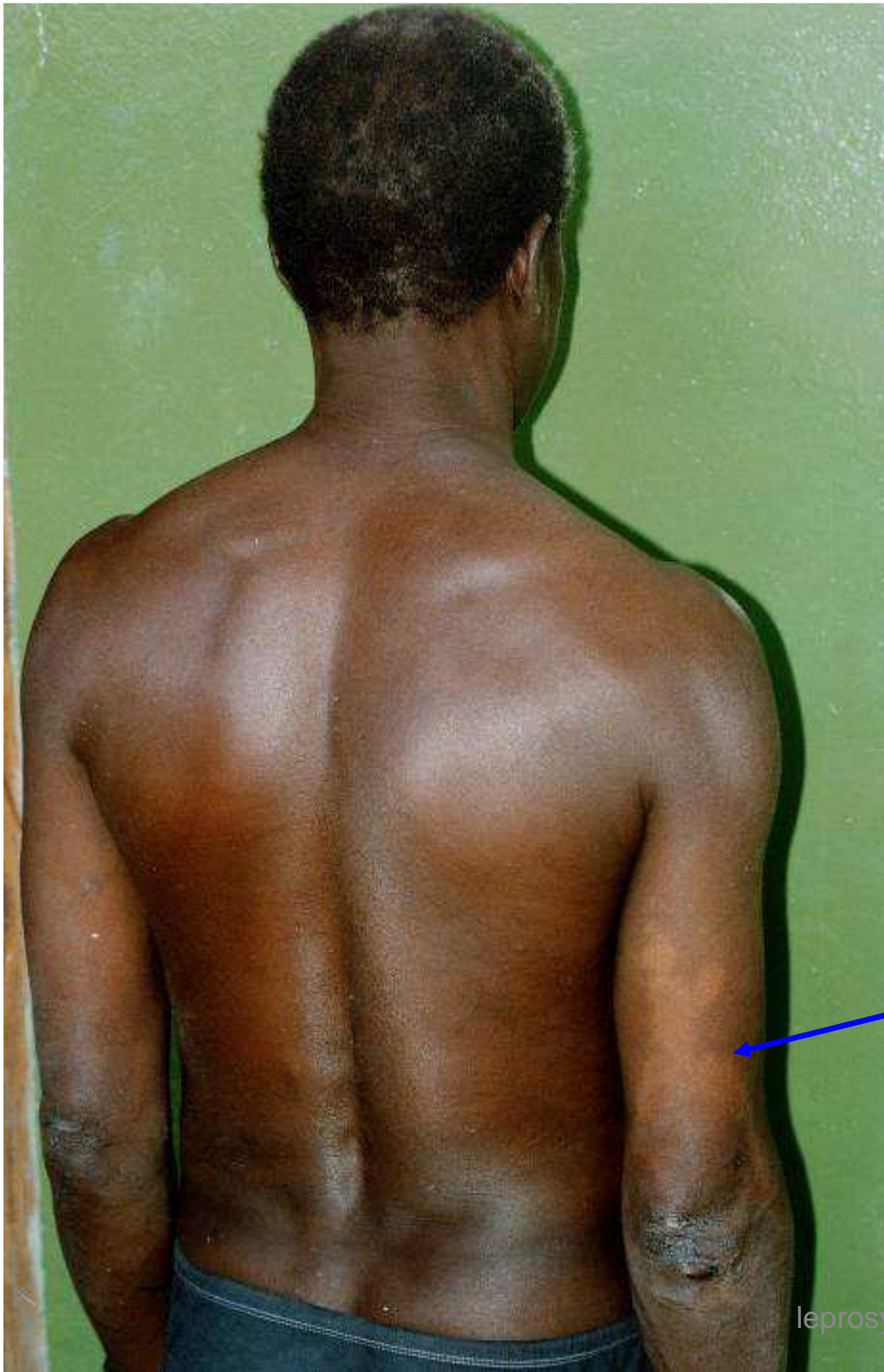
Courtesy of B. Naafs



Testing for loss of sensation

1. Explain
2. Demonstrate
3. Test when the patient comprehends fully

Courtesy of: S Noto



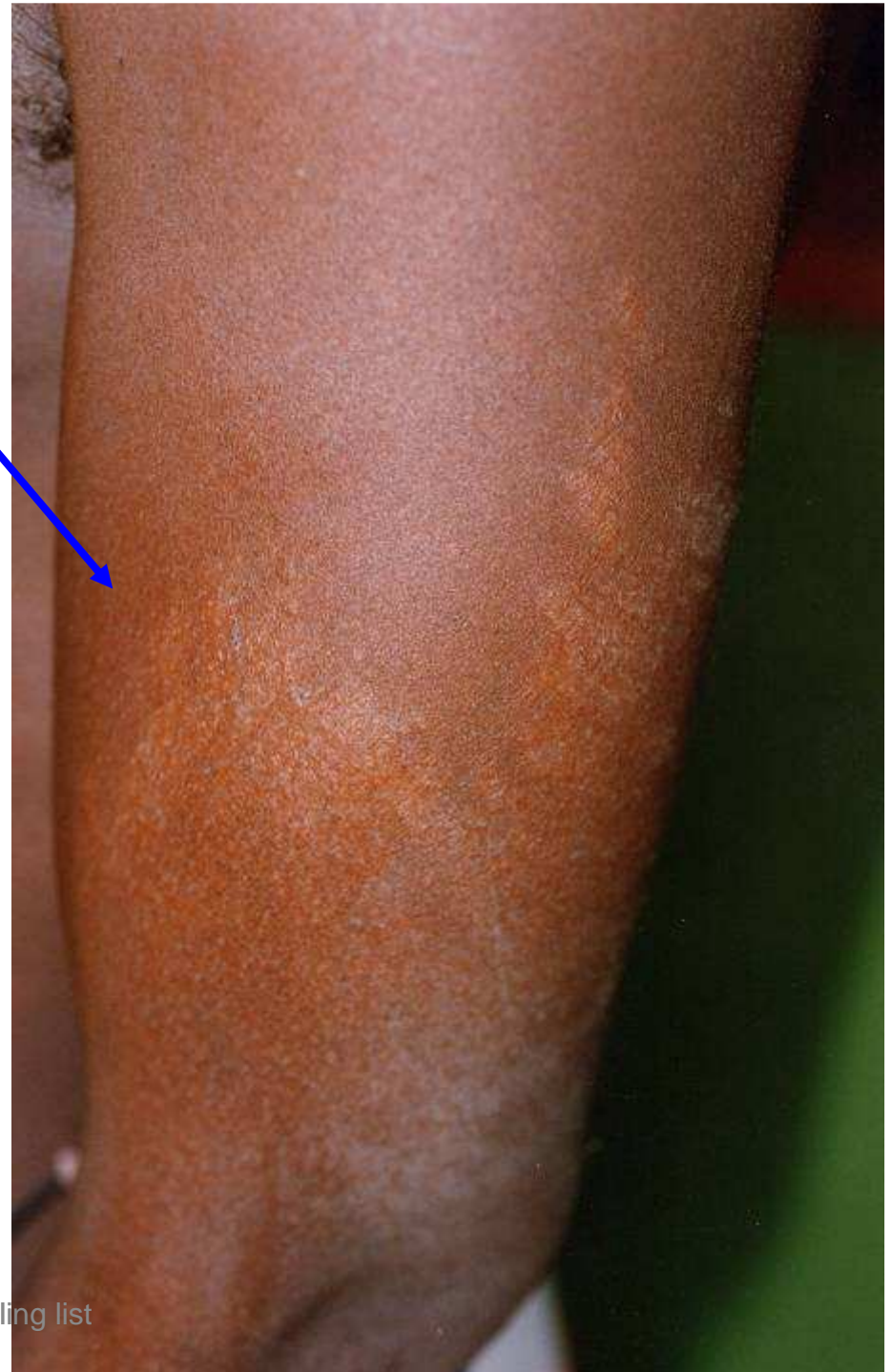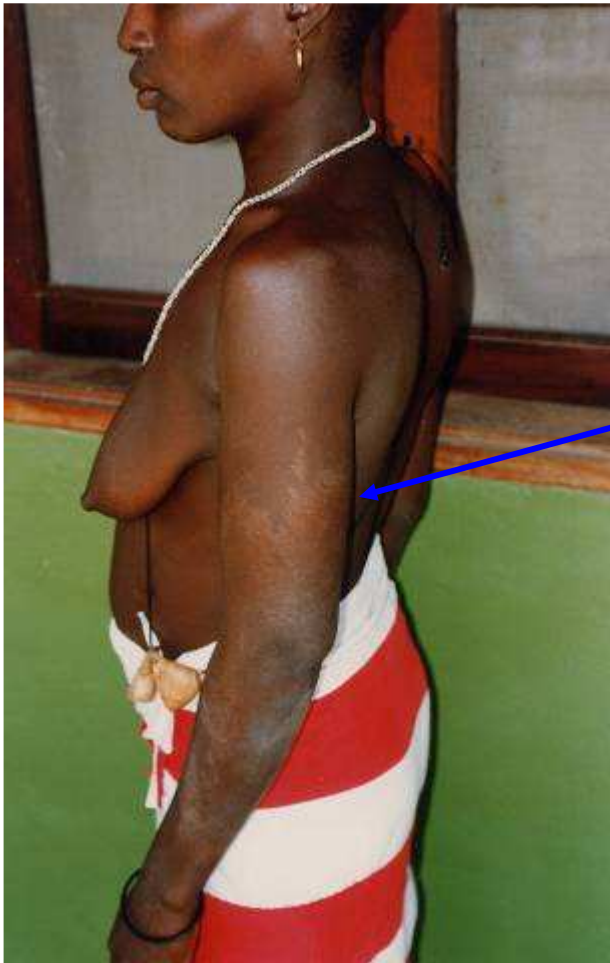
- Hypopigmentation
- Distribution
- Margins
- Streaming and satellite lesions

Loss of sensation? Yes

Leprosy

Courtesy of: S Noto

leprosy mailing list



- Distribution
- Margins
- Streaming and satellite lesions
- Surface is dry

Loss of sensation? Yes.

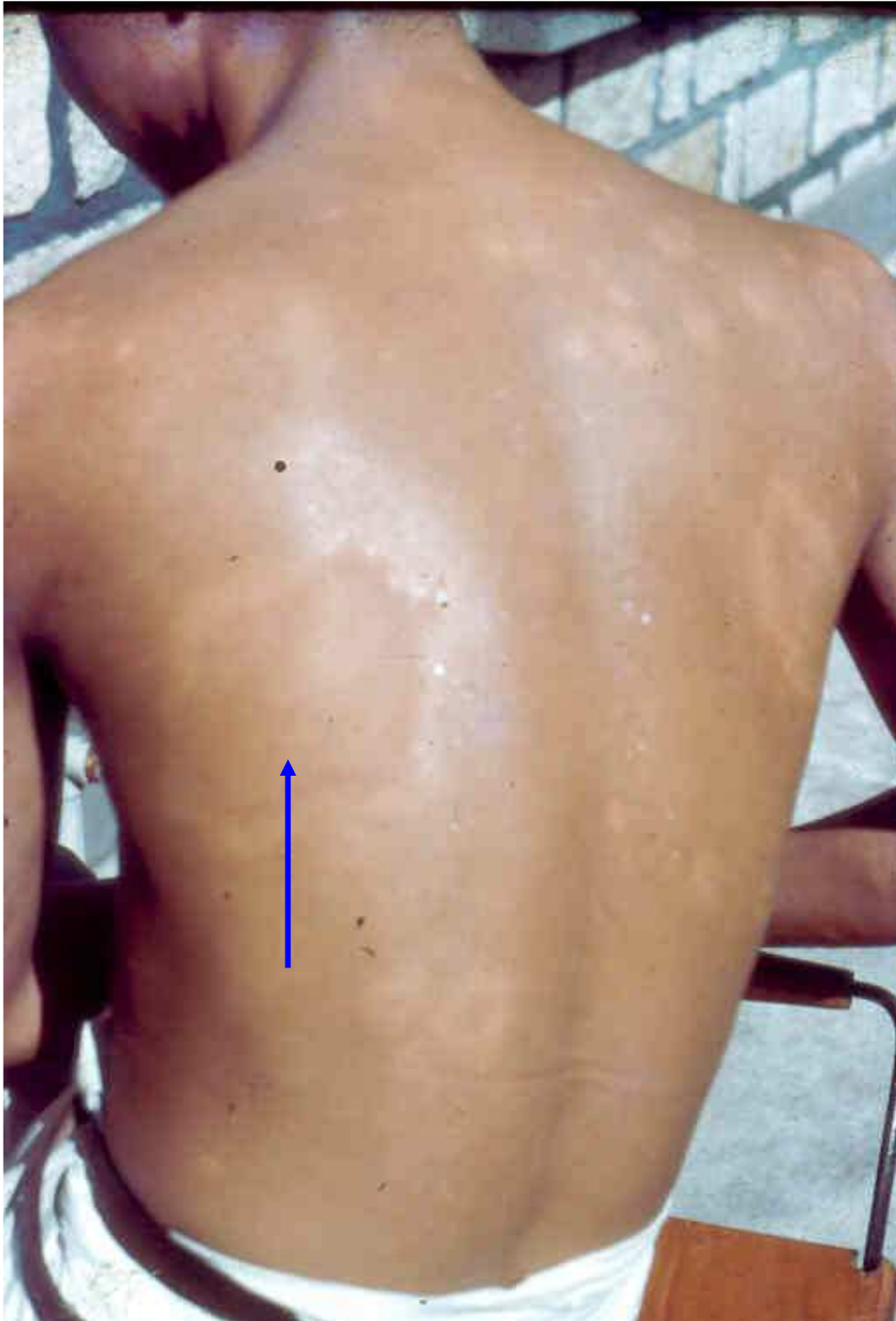Leprosy

Courtesy of: S Noto

leprosy mailing list

Addendum

The sweat and histamine tests

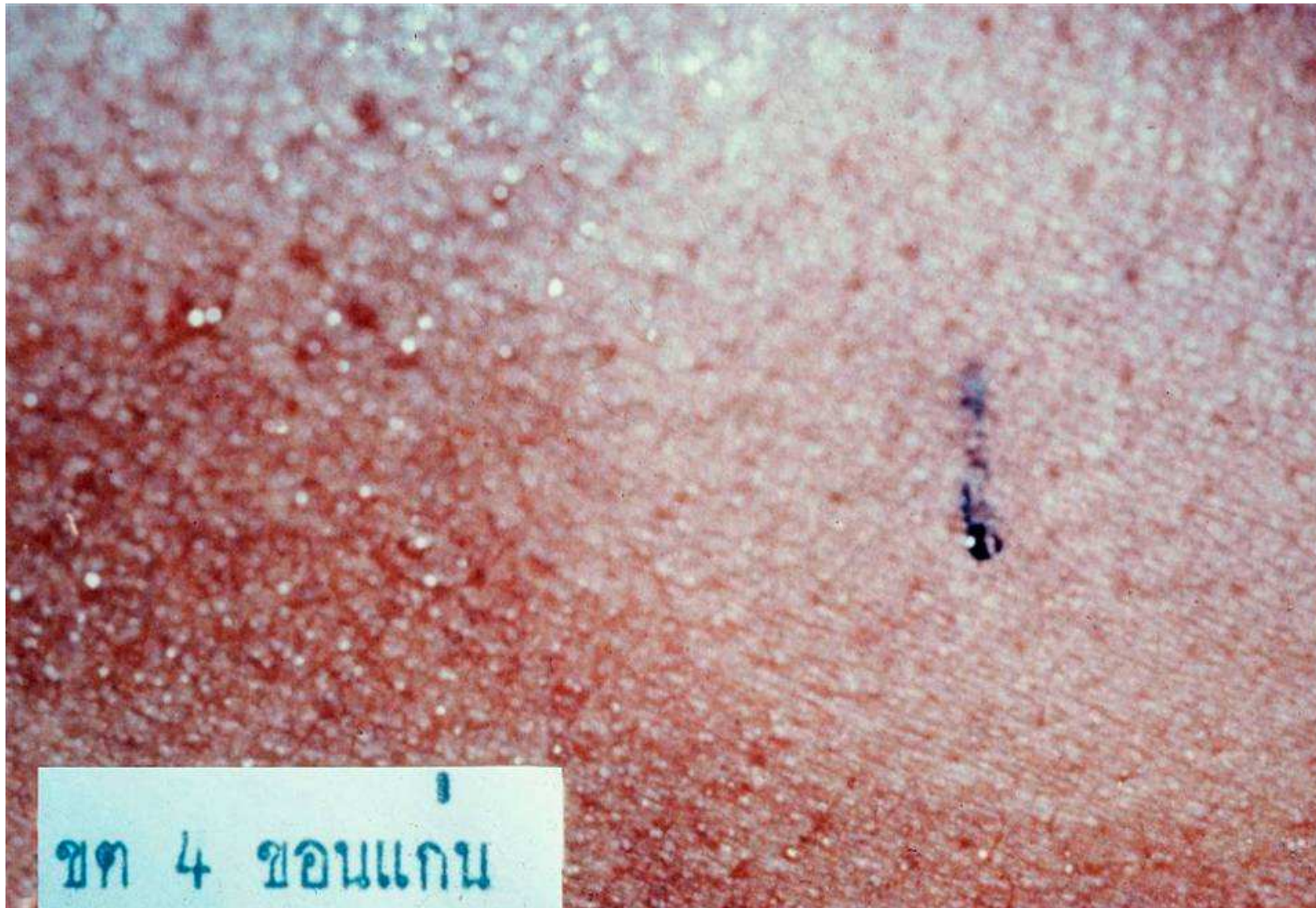

Loss of sweating in hypopigmented leprosy macules

Borderline leprosy

The big leprosy lesion (arrow) is definitely dry while the normal skin is shiny from the reflection from the moisture of the sweat.

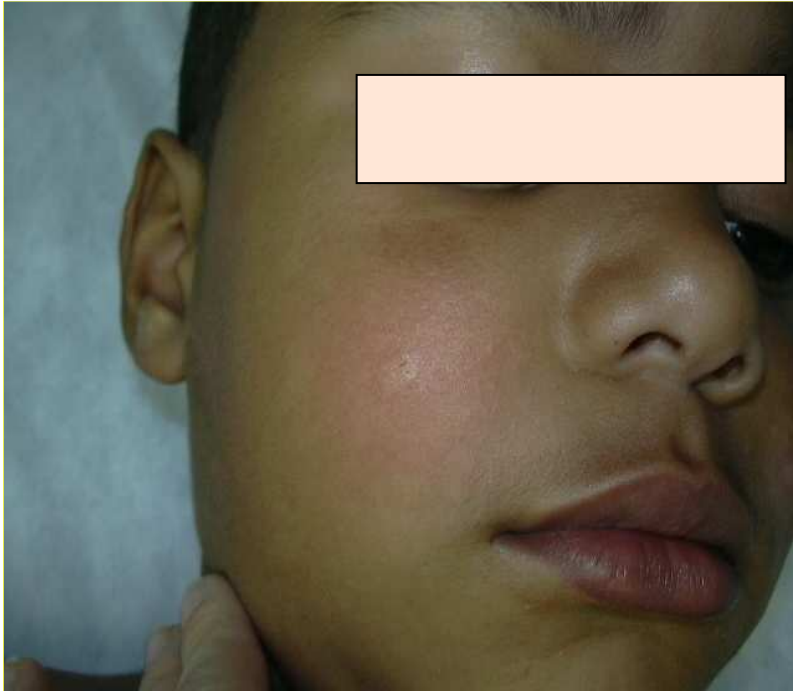Courtesy of Grace Warren



ชต 4 ขอนแก่น

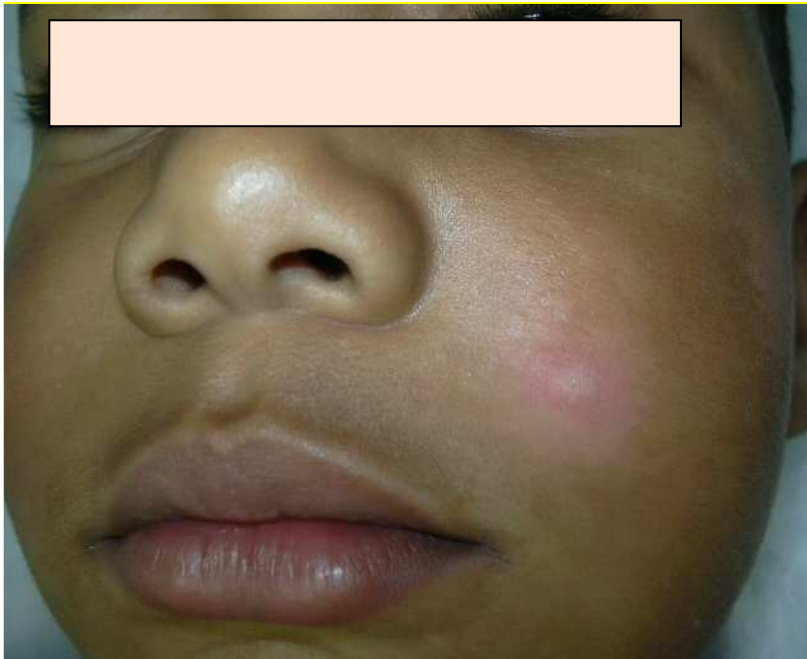Loss of sweating in hypopigmented leprosy macula

On the right side of the slide a round dry hypopigmented leprosy lesion.
On the left normally pigmented skin with drops of sweat



The histamine test

Normal response (redness) to injection of histamine = normal skin



Diminished response (reduced redness) to injection of histamine = leprosy lesion

Courtesy of J A da Costa Nery